

Accepted Manuscript

Title: Eye Movements Differ Between Ictal Ipsilateral and Contralateral Head Turning

Author: Leyla Baysal Kirac Jan Rémi Anna Mira Loesch
Elisabeth Hartl Christian Vollmar Soheyl Noachtar



PII: S0920-1211(15)00071-6
DOI: <http://dx.doi.org/doi:10.1016/j.eplepsyres.2015.03.016>
Reference: EPIRES 5351

To appear in: *Epilepsy Research*

Received date: 2-1-2015
Revised date: 7-3-2015
Accepted date: 28-3-2015

Please cite this article as: Kirac, L.B., Rémi, J., Loesch, A.M., Hartl, E., Vollmar, C., Noachtar, S., Eye Movements Differ Between Ictal Ipsilateral and Contralateral Head Turning, *Epilepsy Research* (2015), <http://dx.doi.org/10.1016/j.eplepsyres.2015.03.016>

This is a PDF file of an unedited manuscript that has been accepted for publication. As a service to our customers we are providing this early version of the manuscript. The manuscript will undergo copyediting, typesetting, and review of the resulting proof before it is published in its final form. Please note that during the production process errors may be discovered which could affect the content, and all legal disclaimers that apply to the journal pertain.

Highlights

Sequence of head and eye movements is different in ictal ipsi and contralateral turns.

Eye and head movements in epileptic seizures are generated by different mechanisms.

Eye and head movement directions may distinguish ictal ipsi and contralateral turns.

Accepted Manuscript

Eye Movements Differ Between Ictal Ipsilateral and Contralateral Head Turning

Leyla Baysal Kirac^{1,2*}, Jan Rémi^{1*}, Anna Mira Loesch¹, Elisabeth Hartl¹, Christian Vollmar¹, and Soheyl Noachtar¹

¹ Epilepsy Center, Department of Neurology, University of Munich, Marchioninstr. 15, 81377, Munich, Germany

² Department of Clinical Neurophysiology, Department of Neurology, Istanbul University, Istanbul Medical School, Fatih/Çapa 34093 Istanbul, Turkey

Corresponding author

Prof. Dr. Soheyl Noachtar
Epilepsy Center, Dept. of Neurology
University of Munich
Marchioninstr. 15, 81377 Munich, Germany
Phone: +49-89-7095 3691
Fax: +49-89-7095 6691
Email: noa@med.uni-muenchen.de

² Permanent address

* Both authors contributed equally

Eye Movements Differ Between Ictal Ipsilateral and Contralateral Head Turning

ABSTRACT

Purpose: This study evaluated the relation of head and eye movements during ictal ipsilateral and contralateral head turning in patients with focal epilepsies with regard to lateralization of the epileptogenic zone.

Methods: We reviewed our data base and identified patients with ictal head turning ipsilateral and contralateral to the seizure onset as defined by ictal EEG. Twenty-seven seizures of 19 consecutive patients with ipsilateral and 40 seizures of 32 patients with contralateral head turning were investigated. Twenty-four patients had temporal lobe epilepsy (TLE), and 27 patients had extratemporal or multifocal epilepsy.

Key Findings: Eye movement in the same direction preceded contralateral head turning in 90% (36 of 40 seizures) of the seizures, but this was the case in only 33% (9 of 27 seizures) of the ipsilateral ictal head turning. In contrary, head turning preceded the eye movements in 67% (18 of 27 seizures) of the ipsilateral ictal head turning and in only 10% of the contralateral head turning ($p < 0.001$). The results were similar in TLE and FLE.

Significance: The sequence of head and eye movements is different in ictal ipsilateral and contralateral head turning movements which likely reflects different spread patterns of epileptic activity associated with activation of different generators. The analysis of eye movements adds to the lateralization of ictal head movements.

Key words: Ictal head turning, frontal eye field, saccadic eye movements, temporal lobe epilepsy, frontal lobe epilepsy, version

1. INTRODUCTION

Head turning is a common seizure phenomenon in patients with focal epilepsies and was reported to have a high lateralizing significance (Wyllie et al., 1986). This finding was challenged by some studies which attributed no lateralizing significance to head movements since both, ipsilateral and contralateral head movement were observed during epileptic seizures of patients with focal epilepsies (Ochs et al., 1984). This controversy was resolved by the observation that the initial ipsilateral head movement was followed by a contralateral movement has a high lateralizing value (Abou-Khalil and Fakhoury, 1996; O'Dwyer et al., 2007; Rémi et al., 2011). Electrical stimulation of the frontal eye field leads to contralateral eye and head movements identical to the ictal movements recorded during epileptic seizures (Godoy et al., 1990). However, little is known about the relation between the head and eye movements in ipsilateral head turning and their generators. In order to better understand the relation of eye and head movement in terms of correct lateralization, we evaluated the relation of head and eye movements in both ictal ipsilateral and contralateral head turning.

2. METHODS

2.1 Patient population

Patients with seizure associated head turning regardless of its direction were collected from the database of Epilepsy Monitoring Unit of the University of Munich. The direction of head movements as ipsilateral or contralateral was defined according to the hemisphere of seizure onset by ictal electroencephalography (EEG). All patients had been admitted to the Epilepsy Monitoring Unit for presurgical evaluation or differential diagnosis of epilepsy.

We searched the database of the University of Munich Epilepsy Monitoring Unit for the patients who had head turning during the evolution of their seizure. We included 51 consecutive patients (mean age 34.5 ± 12.4 , range 16-77 years; mean duration of epilepsy was 13 ± 9 years; female/male ratio 22/29) who fulfilled the inclusion and exclusion criteria described below. Of all 304 patients with head movements, we selected 19 consecutive patients with ipsilateral head turning and compared them with 32 consecutive patients with contralateral head turning. Twenty-four patients had temporal lobe epilepsy (TLE), and 27 patients had extratemporal or multifocal epilepsy. All patients underwent a detailed presurgical evaluation with clinical examination, seizure history and prolonged video EEG monitoring with scalp (n=41) or additional intracranial electrodes (n=10). All patients had 40-channel non-invasive EEG video monitoring with all 10–20 system electrodes, two sphenoidal electrodes, ECG and additional 10-10 system electrodes. Invasive EEG included stereotactically implanted depth electrodes (n=7) and subdural

strip and grid electrodes (n=3). High resolution magnetic resonance imaging (MRI) according to a standard epilepsy protocol, and ictal and interictal single-photon emission computed tomography (SPECT) (n=23) or fluorodeoxyglucose positron emission tomography (FDG-PET) (n=12) were performed in selected patients. All patients were discussed in a multidisciplinary case management conference based on the results of EEG-video monitoring, MRI, PET and SPECT findings. The syndrome diagnosis was supported by at least two congruent results from EEG and imaging studies (MRI; SPECT and PET) in 41 patients (81%). In 10 patients (19%) with nonspecific MRI and functional imaging findings, the lateralization of the epileptic zone was based on EEG and seizure semiology alone.

2.2 Inclusion and exclusion criteria

Seizure videos were included when the quality of the video recording allowed analysis of the eye and head movements. We included only those seizures in which eye and head turning lasted at least 2 seconds and was greater than approximately 30 degrees from the baseline head and eye position. Seizures were excluded if the head turning movement was associated with external stimuli such as head turning to a EEG-technician approaching the patient during a seizure or if the head turning was not fully visible in the recording. The direction of eye and head movements were identified based on visual analysis by two epileptologists (L.B.K. and J.R.) and defined as contralateral and

ipsilateral according to the EEG ictal patterns independently. Only the first direction of head movement was included in the evaluation in those patients who had head turns in different directions during the same seizure. Seizures in which the ictal EEG was non-lateralised were excluded.

2.3 Eye and Head movements

The cohort was divided into four groups according to the sequence of head movements and gaze shifts during head turning.

- 1) Eyes turning contralaterally followed by head turning in the same direction:
Contralateral eyes leading. (Simultaneous contralateral movements of eye and head were included here).
- 2) Head turning contralaterally followed by eyes turning in the same direction:
Contralateral head leading.
- 3) Eyes turning ipsilaterally followed by head turning in the same direction:
Ipsilateral eyes leading. (Simultaneous ipsilateral movement of eye and head was included here).
- 4) Head turning ipsilaterally followed by eyes turning in the same direction:
Ipsilateral head leading.

2.4 Statistical analysis

Statistical analyses were performed using the Fisher's exact test. We analyzed 67 seizures in 51 patients. Therefore, not all data would be independent. Hence we only included the first analyzed seizure in the patient that contributed more than one seizure. Attaining statistical significance was not changed by this limitation. Results were considered statistically significant when $p < 0.05$. Interrater reliability was computed using kappa (k) statistics.

3. RESULTS

Head turning was contralateral to the side of epileptogenic zone in 40 seizures of 32 patients and ipsilateral in 27 seizures of 19 patients. Eyes were leading contralateral head movement in 90% (36 of 40 seizures) of the seizures but in only 33% (9 of 33 seizures) of ipsilateral head turning. In contrary, the head movement was leading (followed by eye turning) in 67% (18 of 27 seizures) of the ipsilateral and in 10% (4 of 40 seizures) of the contralateral head turning ($p < 0.001$) (Figure 1). The interrater variability in the assessment of the eye and head movement sequence was excellent ($k = 0.88$).

Ipsilateral head turning was as common in temporal and frontal onset seizures as it occurred in 47% (18 of 37 seizures) of seizures arising from temporal and 37% (7 of 19

seizures) of seizures arising from frontal lobe (Table 1). Ipsilateral head leading was observed in 72% (13 of 18 seizures) of the temporal and 71% (5 of 7 seizures) of the frontal onset seizures. However, contralateral eyes leading was present in 89 % (17 of 19 seizures) of temporal and 92 % (12 of 13 seizures) of frontal onset seizures. Occipital and temporo-occipital onset seizures (n=6) were never associated with head leading in either ipsi- and contralaterally direction (Table 1). Since one patient could only be lateralized and not localized the table reflects the data of 66 patients.

Contralateral head turning was more commonly associated with evolution into generalized convulsive seizures (87.5%, 35 of 40 seizures) than ipsilateral head turning (48%, 13 of 27 seizures) ($p<0.01$). Ipsilateral preceded contralateral head turning in 52% (14 of 27 seizures) of the seizures including 11 seizures (79%, 11 of 14 seizures) which generalized secondarily. In only two seizures ipsilateral head turning evolved into generalized convulsive seizures without succeeding contralateral head turning. The head turning in these two patients was 40s and 8s before the secondary generalization. Contralateral preceded ipsilateral head turning in only one patient.

In 13 seizures (of 9 patients) there were only ipsilateral head turnings which were not preceded by contralateral head turnings. Ten seizures (of 6 patients) showed head and 3 seizures of 3 patients showed ipsilateral eyes leading head turning. Additionally, 5 seizures (of 2 patients) with contralateral eyes leading head turning did not evolve into generalized convulsions. Hence the analysis of head movement alone did not identify

correct lateralization in 11 out of 51 patients. In 8 of these 11 patients, analysis of eye movements relative to the head movement allowed correct lateralization.

Eye movement direction identified by using the surface EEG recordings supported the results of video analysis in 16 of 53 (31 %) seizures (Figure 2). The other recordings were obscured by seizure related artifacts. The video results were consistent with the EEG results on eye movement in the cases where we had both available. Head turning was contralateral to the side of epileptogenic zone in 11 seizures of 9 patients and ipsilateral in 5 seizures of 3 patients. Eyes were leading contralateral head movements in 91 % (10 of 11 seizures) of the seizures and in 20 % (1 of 5 seizures) of ipsilateral head turning. Head movement was leading (followed by eye turning) in 80 % (4 of 5 seizures) of the ipsilateral and 9 % (1 of 11 seizures) of the contralateral head turning ($p=0.01$).

4. DISCUSSION

Our study demonstrates that the sequence of eye and head movements is different in ipsilateral and contralateral head turning movements during epileptic seizures. Contralateral head turning has been described as one of the most robust lateralizing seizure phenomena (Wyllie et al., 1986). However, its lateralizing significance has been challenged (Ochs et al., 1984). The lateralizing value of ictal head turning is high in FLE and TLE if initial ipsilateral head turning is followed by contralateral head movement (Abou-Khalil and Fakhoury, 1996; O'Dwyer et al., 2007; Rémi et al., 2011). The

ipsilateral and contralateral head turning occurs earlier in the seizure course in FLE patients than in TLE patients (Rémi et al., 2011).

Contralateral ictal head version is considered to arise from epileptic activation of the frontal eye field (FEF) since electrical stimulation of the FEF elicits the same sequence of contralateral eye and head turning as observed during epileptic seizures (Godoy et al., 1990). First the eyes turn contralaterally and then the head follows. However, primate stimulation studies favor the concept that there are independent eye and head movement generators (Chen and Tehovnik, 2007). Stimulation of supplementary eye field (SEF) and the superior colliculus may evoke early head or head alone contralateral movements (Chen and Walton, 2005; Chen and Tehovnik, 2007). The pathophysiologic basis of ictal ipsilateral head turning movement remains unknown. It may be due to the complex functional anatomy and the bilateral innervation of the sternocleidomastoid muscles (Jayakar et al., 1992; DeToledo and David, 2001). There is evidence from primate studies that electrical stimulation of the rostral part of nucleus reticularis gigantocellularis (NRG) evokes ipsilateral head turning and eye movements which counter-rotate and lag behind head movements (Quesy and Freedman, 2004). This may result from vestibular neurons which are less sensitive to head movements produced by central commands. Additionally, stimulation of the polysensory zone located behind the arcuate sulcus in the ventral premotor cortex in monkeys generates a defensive response that reacts to head-directed threatening stimuli where the gaze is moved away from an approaching stimulus through the use of a large ipsilateral head movement and centering eye movements (Boulanger et al., 2009). These data support the concept that ipsilateral and contralateral head and eye movements are generated by different mechanisms.

The selection of the videos included in this study was hampered by the fact that the video resolution in a lot of seizure videos was not sufficient to judge on the eye movement direction with regard to the head movement direction. To overcome this methodological difficulty we performed an interrater variability study which showed an excellent consistency between observers for the seizure videos included in the study. The epileptologists who reviewed the videos were not fully blinded to the lateralization of epileptogenic zone as one of the reviewers (J.R.) had previously seen some of the patients clinically. This may be a possible bias, but since the concordance with the other reviewer (L.B.K.) was excellent we believe that this bias does not alter the overall results of this study.

In conclusion, the order of eye and head movements during epileptic seizures varies depending on direction of movement relative to seizure onset zone, suggesting that they are generated by different mechanisms depending on the spread pattern of epileptic activity. Paying attention to the difference of eye movement direction with regard to the ictal head movement may help to distinguish ictal ipsilateral and contralateral head turning.

Acknowledgments

Dr. Baysal Kirac is funded by the ‘Turkish Neurological Society Educational Grant’ for this work.

Disclosure

None of the authors has any conflict of interest to disclose. We confirm that we have read the Journal's position on issues involved in ethical publication and affirm that this report is consistent with those guidelines.

REFERENCES

- Abou-Khalil, B., Fakhoury, T., 1996. Significance of head turn sequences in temporal lobe onset seizures. *Epilepsy Res.* 23, 245-250.
- Boulanger, M., Bergeron, A., Guitton, D., 2009. Ipsilateral head and centring eye movements evoked from monkey premotor cortex. *Neuroreport* 20, 669-673.
- Chen, L.L., Walton, M.M., 2005. Head movement evoked by electrical stimulation in the supplementary eye field of the rhesus monkey. *J. Neurophysiol.* 94, 4502-4519.
- Chen, L.L., Tehovnik, E.J., 2007. Cortical control of eye and head movements: integration of movements and percepts. *Eur. J. Neurosci.* 25, 1253-1264.
- DeToledo, J.C., David, N.J., 2001. Innervation of the sternocleidomastoid and trapezius muscles by the accessory nucleus. *J. Neuroophthalmol.* 21, 214-216.
- Godoy, J., Luders, H., Dinner, D.S., et al., 1990. Versive eye movements elicited by cortical stimulation of the human brain. *Neurology* 40, 296-299.

Jayakar, P., Duchowny, M., Resnick, T., et al., 1992. Ictal head deviation: lateralizing significance of the pattern of head movement. *Neurology* 42, 1989-1992.

Ochs, R., Gloor, P., Quesney, F., et al., 1984. Does head-turning during a seizure have lateralizing or localizing significance? *Neurology* 34, 884-890.

O'Dwyer, R., Cunha, J.P.S., Vollmar, C., et al., 2007. Lateralizing significance of quantitative analysis of head movements before secondary generalization of seizures of patients with temporal lobe epilepsy. *Epilepsia* 48, 524-530.

Quessy, S., Freedman, E.G., 2004. Electrical stimulation of rhesus monkey nucleus reticularis gigantocellularis. *Exp. Brain Res.* 156, 342-356.

Rémi, J., Wagner, P., O'Dwyer, R., et al., 2011. Ictal head turning in frontal and temporal lobe epilepsy. *Epilepsia* 52, 1447-1451.

Wyllie, E., Lüders, H., Morris, H.H., et al., 1986. The lateralizing significance of versive head and eye movements during epileptic seizures. *Neurology* 36, 606-611.

Figure captions:

Figure 1: Comparison of sequence of eye and head movements in ictal ipsilateral and contralateral head turning.

Figure 2: Ictal EEG recording in longitudinal bipolar montage shows rhythmic slow wave activity with an increasing frequency in the left frontotemporal electrodes. Head movement was leading left lateral eye movement in ictal ipsilateral head turning. The grey arrow marks the baseline head and eye position at seizure onset. The black arrow marks the onset of head turning to the left. The red arrow marks the left lateral eye movement lasting 3 seconds as reflected by positivity in F7 and negativity in F8 generated by the dipole of the eye (In order to identify slow eye movements, the low frequency filter has to be lowered to at least 0,1 s).

Table**Table 1:** Sequence of head and eye movements in ictal ipsilateral and contralateral head turning according to the seizure onset zones

	Ipsilateral n=27		Contralateral n=39	
	Eyes leading	Head leading	Eyes leading	Head leading
¹ Temporal n=37	5	13	17	2
¹ Frontal n=19	2	5	11	1
Temporoparietal n=4	-	-	3	1
Temporooccipital n=3	1	-	2	-
Occipital n=3	1	-	2	-

¹ denotes statistical significance at $p < 0.001$ (Fisher's exact test) for comparison of ictal ipsilateral and contralateral head turning

Figure 1

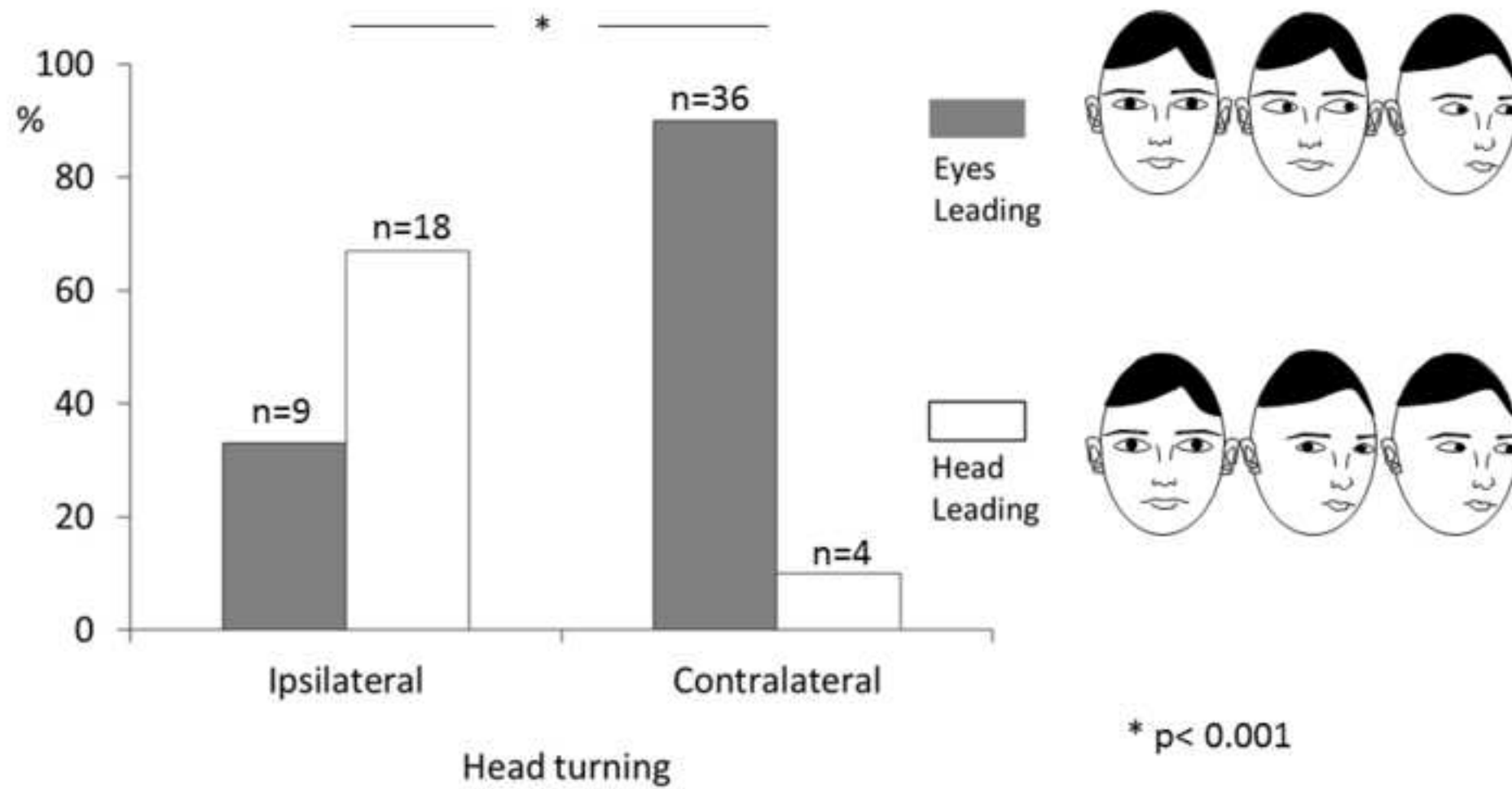
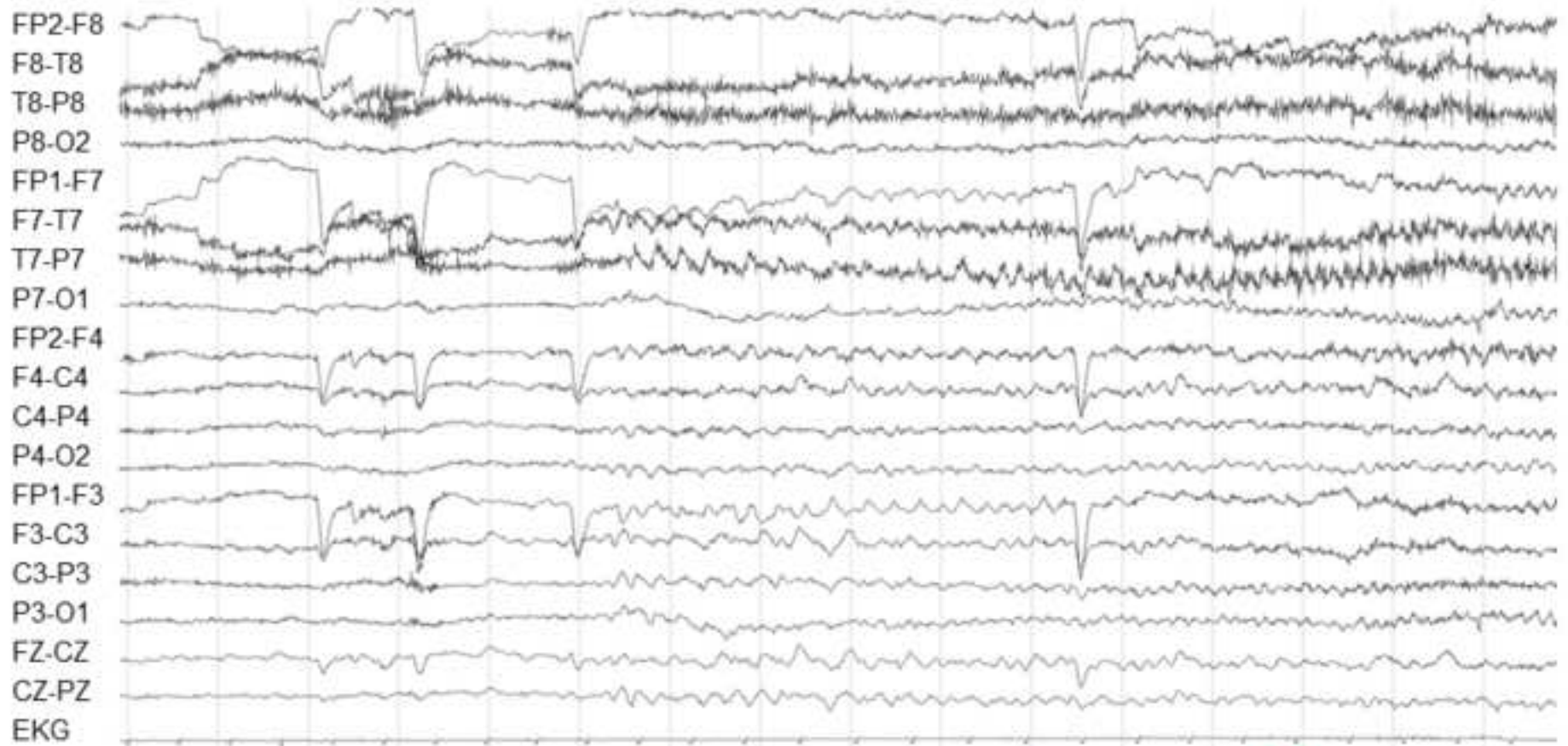


Figure 2



200 μ V
1 s

